



A rare variation of the branching pattern of radial nerve

Published online February 17th, 2011 © <http://www.ijav.org>Jamuna M ⁺

Department of Anatomy, PSG Institute of Medical Sciences and Research, Coimbatore, Tamilnadu, INDIA.



⁺ Dr. Jamuna M, MS
Associate Professor
Department of Anatomy
PSG Institute of Medical Sciences and Research
Peelamedu, Coimbatore
Tamilnadu, INDIA.
☎ +91 944 97 97588
✉ drjamunam@gmail.com

Received July 16th, 2010; accepted January 30th, 2011

ABSTRACT

Variation in the branching pattern of posterior cord of the brachial plexus is common but variation in the branching pattern of the radial nerve is rare. A rare and unreported variation in the branching pattern of the radial nerve was noted in the left sided axilla of an embalmed adult male cadaver during the regular gross anatomical dissection for undergraduate students. The radial nerve was having its origin from the posterior cord as a terminal branch and it split into anterior and posterior divisions. Branches of the radial nerve in the arm were given off from the posterior division and the anterior division continued as the main radial nerve with normal course and relations. These variations are important in evaluating post-traumatic injuries and repair of peripheral nerve injuries and during flap dissections. © IJAV. 2011; 4: 22–24.

Key words [posterior cord] [radial nerve] [brachial plexus] [anterior division] [posterior division]

Introduction

The brachial plexus is an ordered network of large nerves through which the sensory and motor nerve supply is distributed to all structures that constitute the upper limb. It is formed by the anterior rami of C5 to T1 spinal nerves. They unite to form the upper, middle and lower trunks. Each trunk splits into anterior and posterior divisions. All three posterior divisions merge to form the posterior cord; in it are gathered all C5 to T1 nerve fibers for the extensor compartment. The posterior cord terminates in the axillary and radial nerves. The radial nerve is the continuation of the posterior cord in the axilla with root value of C5, 6, 7, 8 and T1. Here it gives off the nerve to the long head of triceps, medial head of triceps, posterior cutaneous nerve of the arm, then passes into the groove for radial nerve on the posterior surface of humerus, winding spirally round the posterior surface of the humerus in contact with the periosteum. In the groove the nerve gives off branches to the lateral head of triceps. The nerve then pierces the lateral intermuscular septum and descends in the anterior compartment and ends by dividing into superficial and deep branches. Here a rare variation in the branching pattern of radial nerve in axilla is reported.

Case Report

The present variation was observed during routine gross anatomical dissection class for undergraduate students in PSG Institute of Medical Sciences & Research. The pectoral region, axilla and arm were dissected. The brachial plexus was dissected on both right and left sides of the cadaver. The cords and the branches of the cords of the brachial plexus were identified. The radial nerve was originating from the posterior cord as one of the terminal branches in the infraclavicular part of the brachial plexus, in the left sided axilla of an embalmed adult male cadaver. The radial nerve after having its origin from the posterior cord was splitting into anterior and posterior divisions after having a short course for 1 cm in the axilla. Both the divisions had their course in the radial groove and the posterior division was giving off the branches which are expected to have origin from the main radial nerve. The posterior division was giving off the muscular and cutaneous branches in the arm. The anterior division continued as the main radial nerve in the radial groove and had a usual course in the rest of the upper limb. In the cubital fossa the anterior division was splitting into superficial and deep branches which had their usual course.

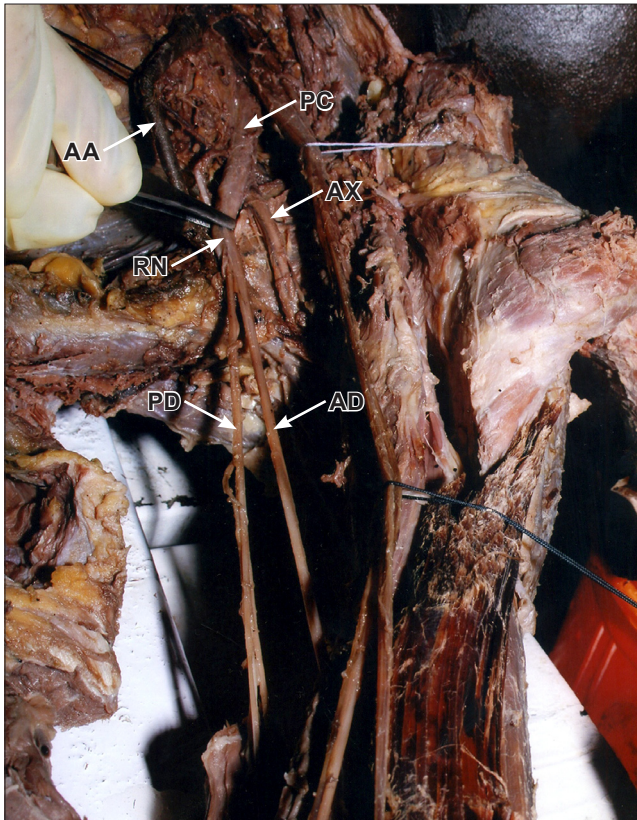


Figure 1. Radial nerve splitting into anterior and posterior divisions. (*PC*: posterior cord; *AA*: axillary artery; *AX*: axillary nerve; *RN*: radial nerve; *PD*: posterior division; *AD*: anterior division)

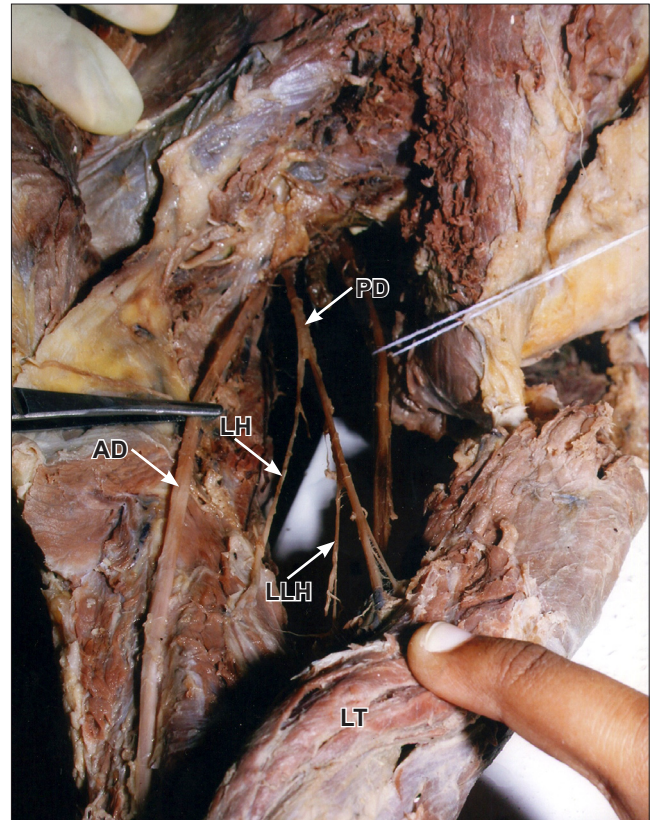


Figure 2. Radial nerve in posterior compartment of arm. (*PD*: posterior division; *AD*: anterior division; *LH*: nerve to lateral head of triceps; *LLH*: nerve to long head of triceps; *LT*: long head of triceps)

Discussion

Variations in the formation of radial nerve have been reported in the literature quite frequently, but variation in the branching pattern of the radial nerve has not been reported. In one case there was a report that the posterior cord divided into two roots, enclosing the subscapular artery and the two roots fused to continue as radial nerve [1]. Kuwar also reported in a case where the radial nerve had two roots arising from the posterior cord and the two roots were clasping the subscapular artery [2]. In contrary to the above reports, the radial nerve was originating from the posterior cord as a terminal branch, but after a short distance it was splitting into anterior and posterior divisions. Bertha et al. reported in one case instead of a single entity, the posterior cord had two parts as upper and lower; the upper posterior cord continued as axillary nerve and gave off the upper root of radial nerve, the lower posterior cord continued as the lower root of radial nerve and joined with the upper root to form radial nerve [3]. There was a report in a case where the radial nerve was arising from the union of posterior division of inferior trunk and the middle trunk and there was no contribution from the superior trunk [4]. Oluymi et al. also have reported the radial nerve to have

origin from the posterior aspect of the medial cord where the cords were found to be present as medial and lateral cords [5]. In another case study there was accessory radial root which arose from the inferior trunk and was communicating with the root which had its origin from the posterior cord to form the radial nerve [6]. These variations are not similar to the present study where the formation of radial nerve was as usual but the radial nerve only was splitting into anterior and posterior divisions. Gupta et al. described the variations in plexus patterns may be due to unusual formation during the development of trunks, divisions or cords [7]. This variation can be explained embryologically, as the axons of spinal nerves grow distally to reach the limb bud mesenchyme, the peripheral processes of the motor and sensory neurons grow in the mesenchyme, in different direction [8]. Neurons formed any developmental differences would obviously persist postnatally [8]. This variation could arise from circulatory factors at the time of fusion of the cords of brachial plexus [9]. Brachial plexus variations are anatomically important because variant nerves with unusual origins, course and distributions are more susceptible to trap neuropathies and injuries during neck dissections [10]. Variations in the branching pattern of radial nerve are rare and it is rarely

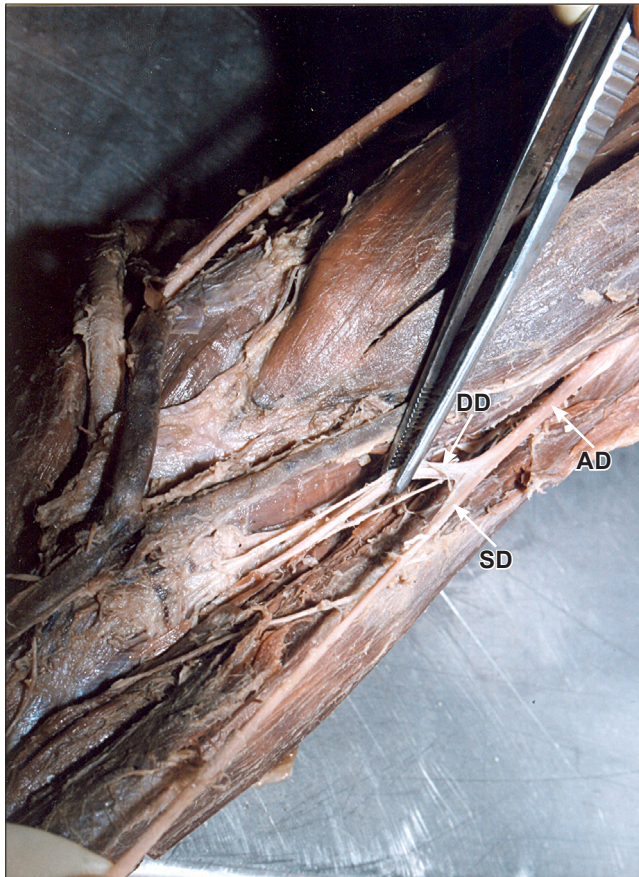


Figure 3. Anterior division of radial nerve in cubital fossa. Anterior division (AD) splitting into superficial division (SD) and deep division (DD).

reported in the literature. This type of variation should be remembered during shoulder arthroscopy and shoulder reconstructive surgeries and neurotization of brachial plexus lesions and performing surgery for tumors of the brachial plexus region. Anatomists and surgeons should be aware of this variation while doing dissection and surgeries in order to prevent any damage to the structures. Since the nerve palsy syndromes can be caused by the anatomical variations of the peripheral nerves, awareness of this variation is useful in clinical practice.

References

- [1] Bhat KMR, Girijavallabhan V. Variation in the branching pattern of posterior cord of brachial plexus. *Neuroanatomy*. 2008; 7: 10–11.
- [2] Kuwar RB, Bilodi AK. Claspings of subscapular artery by radial nerve. *Kathmandu Univ Med J (KUMJ)*. 2007; 5: 253–255.
- [3] Bertha A, Kulkarni NV, Maria A, Jestin O, Joseph K. Entrapment of deep axillary arch by two roots of radial nerve – an anatomical variation. *J Anat Soc India*. 2009; 58: 40–43.
- [4] Aktan ZA, Ozturk L, Bilge O, Ozer MA, Pinar YA. A cadaveric study of the anatomic variations of the brachial plexus nerves in the axillar region and arm. *Turk J Med Sci*. 2001; 31: 147–150.
- [5] Oluyemi KA, Adesanya OA, Ofulori DA, Okwuonu CU, Ukwenya VO, Om'iniabofo FA, Odion BI. Abnormal pattern of brachial plexus formation: an original case report. *The Internet Journal of Neurosurgery*. 2007; Volume 4: Number 2.
- [6] Honma S, Kawai K, Koizumi M, Yoshinaga K, Tanii I, Kodama K. An aberrant axillary artery penetrating the origin of the radial nerve from deep to superficial. *Ann Anat*. 2004; 188: 153–156.
- [7] Gupta M, Goyal N, Harjeet. Anomalous communications in the branches of brachial plexus. *J Anat Soc India*. 2005; 54: 22–25.
- [8] Brown MC, Hopkins WG, Keynes R.J. *Essentials of Neural Development*. Cambridge, Cambridge University Press. 1991; 46–66.
- [9] Kosugi K, Mortia T, Yamashita H. Branching pattern of the musculocutaneous nerve. 1. Cases possessing normal biceps brachii. *Jikeikai Medical Journal*. 1988; 33: 63–71.
- [10] Saeed M, Rufai AA. Median and musculocutaneous nerves: variant formation and distribution. *Clin Anat*. 2003; 16: 453–457.