



## A rare muscular variation in the flexor compartment of the forearm

Published online June 24th, 2011 © <http://www.ijav.org>Vishal KUMAR<sup>[1]</sup> +Naveen NS<sup>[2]</sup>Murlimanju BV<sup>[3]</sup>Prima S. D'SOUZA<sup>[1]</sup>

Department of Anatomy, K.S. Hegde Medical Academy, Nitte University, Mangalore [1], Department of Anatomy, K.M.C.T. Medical College, Calicut University, Calicut [2], Department of Anatomy, Kasturba Medical College, Manipal University, Mangalore [3], INDIA.



+ Vishal Kumar, MD  
Assistant Professor  
Department of Anatomy  
K.S. Hegde Medical Academy  
Nitte University  
Deralakatte, Nithyananda Nagar  
Mangalore, 575004, INDIA.  
☎ +91 824 2204480  
✉ vishalanat@gmail.com

Received September 3rd, 2010; accepted May 26th, 2011

### ABSTRACT

We report a rare muscular variation in which some accessory tendons were connecting the flexor pollicis longus and flexor digitorum profundus. The common tendon formed by the joining of the accessory tendons from these muscles was inserting into the tendon of the index finger of flexor digitorum profundus. The surgical anatomy of this variation is important for the orthopedic surgeons since such a variation can cause chronic inflammation, nerve compressions, tenosynovitis and may require surgical excision. © IJAV. 2011; 4: 115–116.

**Key words** [accessory] [flexor digitorum profundus] [flexor pollicis longus] [tendinous connection] [variation]

### Introduction

The accessory heads of the deep flexors of the forearm (Gantzer's muscles) have been described as two different small bellies which insert either into flexor pollicis longus (FPL) or flexor digitorum profundus (FDP) [1]. It is not surprising to find that there are many variations in the manner in which the FPL and the FDP are combined, because both have a common phylogenetic derivation from the pronatorflexor group of Humphry [2]. Most of the studies about these two muscle connections describe about the accessory head of FPL, which was taking origin from the coronoid process of ulna or from the medial epicondyle of the humerus. In the present case we observed a rare muscle belly which was arising from the FPL itself. Since this type of variation was not reported hitherto, the case was studied in detail. The embryological basis of this unusual condition is discussed with relevant review of literature and clinical significances are emphasized.

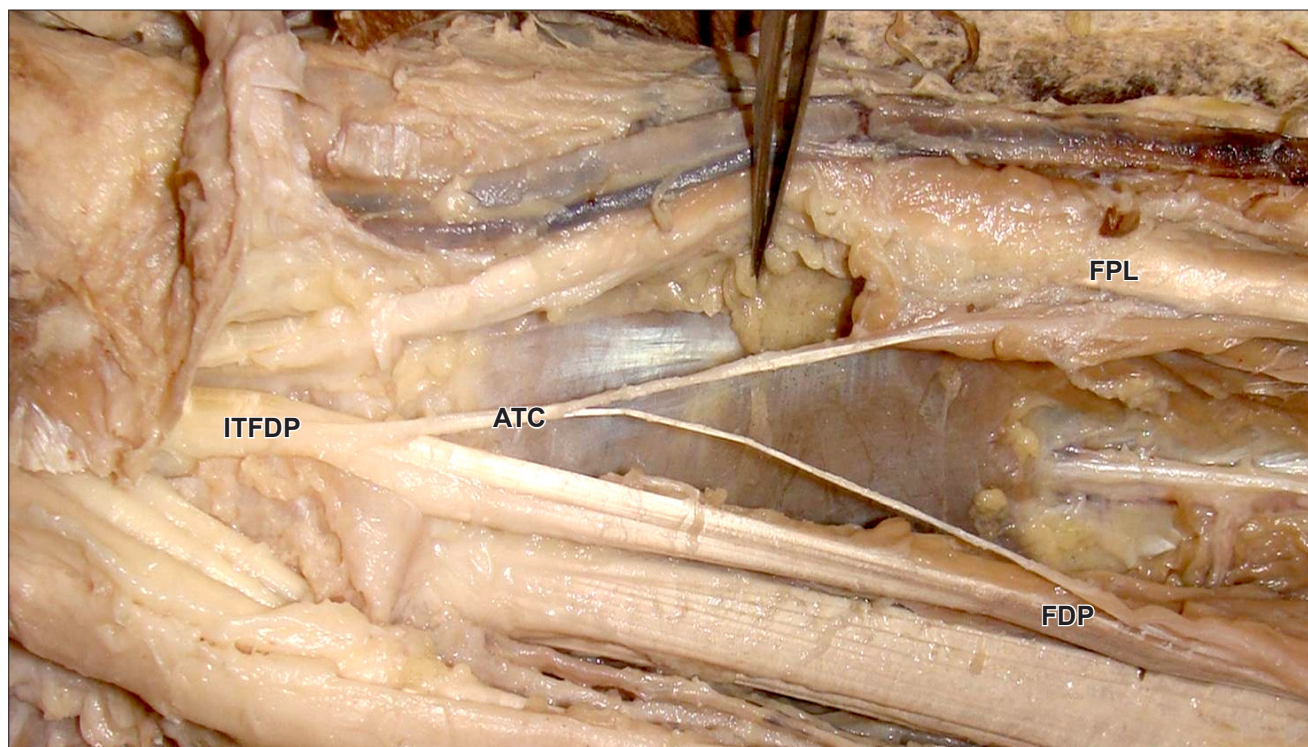
### Case Report

During routine cadaveric dissection done for the undergraduate students at the anatomy laboratory, some variant tendinous slips were observed in the right upper limb of a female cadaver aged around 60 years. The tendinous slips were connecting the FPL and FDP muscles (Figure 1). The accessory muscle took origin as a slender muscular belly

from FPL and then converted to a tendon which was joined by one more tendon arising from the FDP. The common tendon formed by these two accessory tendons was found to be inserting into the tendon of the index finger of FDP.

### Discussion

The existence of accessory muscles which connect the flexor muscles could be explained by the incomplete cleavage of the flexor mass during development [1]. The flexor muscles of the forearm develop from the flexor mass, which subsequently divides into 2 layers, superficial and deep. The deep layer gives rise to the flexor digitorum superficialis, FDP and FPL [3]. So the present variation might have occurred due to incomplete cleavage of the flexor mass during development. It was reported that these variations have clinical relevance in relation to the development of anterior interosseous nerve syndrome and entrapment neuropathy of the median nerve. This has been brought out by the studies of many anatomists as variations consisting of different, more or less intimate connections with the common flexor muscles of the fingers, especially in the flexor profundus [2]. The presence of accessory heads of the deep muscles of the forearm has to be borne in mind in cases of nerve compressions in the forearm frequently, from the median nerve [4]. Linburg and Comstock observed chronic tenosynovitis due to variant connection between flexor pollicis longus and flexor



**Figure 1.** Photograph showing the variant tendinous connections (ATC) between the flexor pollicis longus (FPL) and flexor digitorum profundus (FDP). The variant tendon is inserting into the index finger tendon of flexor digitorum profundus (ITFDP).

digitorum profundus in four of their patients. They observed the incidence rate of this anomaly 31% cases unilaterally and 14% bilaterally. The cadaver studies noted this variant 25% unilaterally and 6% bilaterally [5].

The variant muscle bellies and tendons like this should be kept in mind to avoid clinical complications during radiodiagnostic procedures or surgical approach of these

regions; the accessory heads has been implicated in anterior interosseous nerve syndrome [6]. The surgical anatomy of this variation is important for the orthopedic surgeons since this muscular variation can cause chronic inflammation, nerve compressions, tenosynovitis and may require surgical excision. It is obvious that this report is also important for the anatomists, anthropologists and morphologists.

## References

- [1] Jones M, Abrahams PH, Sanudo JR. Case report: accessory head of the deep forearm flexors. *J Anat.* 1997; 191: 313–314.
- [2] Mangini U. Flexor pollicis longus muscle: its morphology and clinical significance. *J Bone Joint Surg Am.* 1980; 42: 467–470, 559.
- [3] Lewis WH. The development of the muscular system. In: Keibel F, Mall FP, eds. *Manual of Human Embryology.* Vol 1., Philadelphia, J. B. Lippincott. 1910; 482–483.
- [4] El Domiaty MA, Zoair MM, Sheta AA. The prevalence of accessory heads of the flexor pollicis longus and the flexor digitorum profundus muscles in Egyptians and their relations to median and anterior interosseous nerves. *Folia Morphol (Warsz).* 2008; 67: 63–71.
- [5] Linburg RM, Comstock BE. Anomalous tendon slips from the flexor pollicis longus to the flexor digitorum profundus. *J Hand Surg Am.* 1979; 4: 79–83.
- [6] Potu BK, Gorantla VR, Pulakunta T, Rao MS, Mamatha T, Vollala VR, Nayak SR. Accessory head of flexor pollicis longus muscle and its significance in anterior interosseous nerve syndrome: case report and review. *Int J Morphol.* 2007; 25: 911–914.