

## A rare combination of variations of superior mediastinal vessels

Published online February 23rd, 2010 © http://www.ijav.org

Manimay BANDYOPADHYAY<sup>[1]</sup>✉Piyali DAS<sup>[2]</sup>Karabi BARAL<sup>[3]</sup>Rita ROY<sup>[1]</sup>Departments of Anatomy [1] and Physiology [2] Calcutta National Medical College,  
Department of Anatomy RG Kar Medical College [3], INDIA.

✉ Manimay Bandyopadhyay, MBBS, MS  
Associate Professor  
Department of Anatomy  
Calcutta National Medical College  
32, Gopaband Road, Park Circus  
Kolkata-700014, West Bengal, INDIA.  
☎ +91-33-24842892  
✉ manimaybandopadhyay@yahoo.co.in

Received July 17th, 2009; accepted January 6th, 2010

### ABSTRACT

Vessels present in the superior mediastinum are closely related and widely variable. Knowledge of their variation is necessary for cardiothoracic radiology and surgery. We present a case where left vertebral artery originated from the arch of the aorta and left subclavian artery had a narrowing at a site where a vein from the posterior thoracic wall had crossed it. This vein was found to be the accessory azygos vein which had communicated below with hemiazygos vein. The embryological and clinical implications of such a combination of vascular anomalies, probable cause of the narrowing of the subclavian artery are discussed. © IJAV. 2010; 3: 19–21.

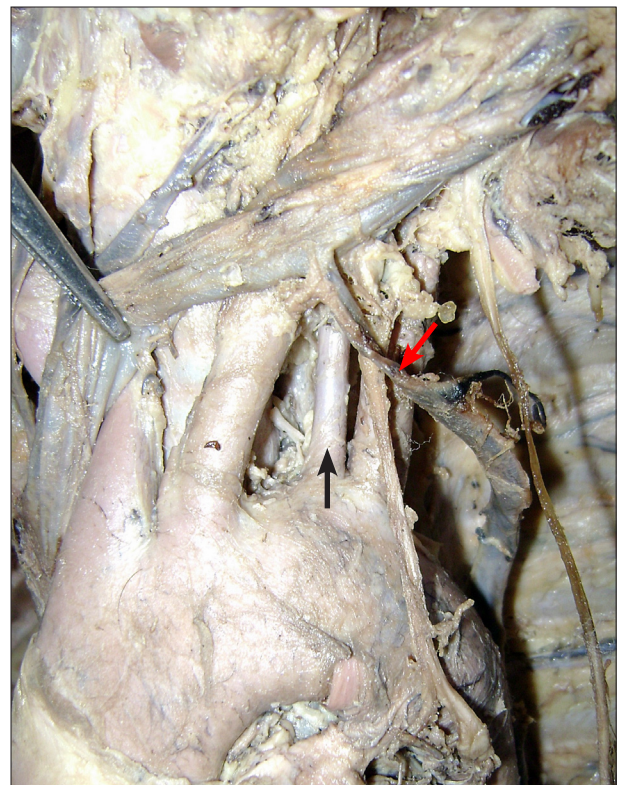
**Key words** [vertebral artery] [subclavian artery] [azygos vein] [hemiazygos vein] [variation]

### Introduction

Superior mediastinum contains many important vessels and tubes, variation of one may affect the other. Left brachiocephalic vein crosses arch of the aorta and its branches superficially. Arch of the aorta from its convex superior aspect usually provides brachiocephalic, left common carotid and left subclavian artery from the right to left. Left subclavian artery continues as axillary artery and becomes the only major source of blood for the upper limb. First part of the subclavian artery on the left side usually provides vertebral, internal thoracic, thyrocervical trunk and costocervical trunk. There is an azygos venous system in the posterior thoracic wall which consists of azygos, hemiazygos and accessory azygos veins. Hemiazygos and accessory azygos veins usually drain into azygos vein at the level of 8th and 7th thoracic vertebra respectively [1].

### Case Report

During routine dissection for undergraduate teaching, a rare variation of the vessels in the superior mediastinum was revealed from a cadaver of a 63-year-old Indian male who died of myocardial infarction. The left brachiocephalic vein received one tributary from below which was found to be the accessory azygos vein. The arch of the aorta was found to give rise to four branches. The additional one was the left vertebral artery arising in between the left subclavian and left common carotid artery. (Figure 1). The left vertebral artery was traced upwards and found to enter the foramen transversarium of 6th cervical vertebra.



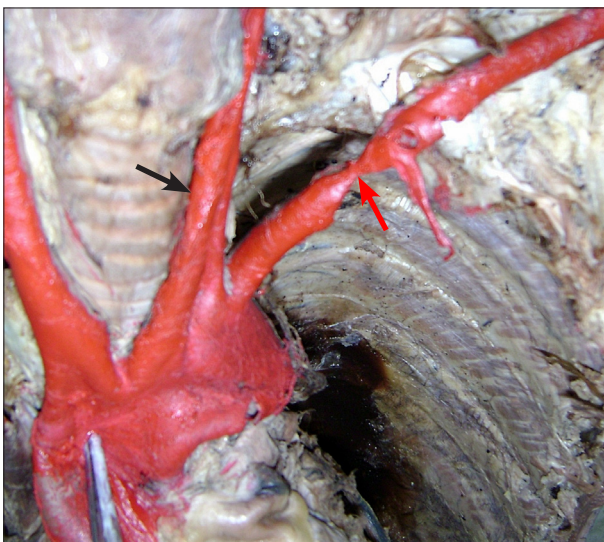
**Figure 1.** Accessory azygos is draining in left brachiocephalic vein. Left vertebral artery is arising from arch of the aorta. (Red arrow: accessory azygos vein; black arrow: left vertebral artery)

The left subclavian artery, just before scalenus anterior muscle, was found to have a constriction. The wall of the artery at the constriction site was very thin and that just proximal to the constriction was found to be very thick (Figure 2). This constriction was not visible before as the accessory azygos vein was crossing the subclavian artery over this site, from the posterior mediastinum to drain into the left brachiocephalic vein. All the branches of the 1st part of the subclavian artery were found to arise distal to the constriction, left vertebral artery being a direct branch of the arch of the aorta. The arterial caliber of the superior extremity on both the sides was same. No variation from normal was detected on the right side. The right vertebral artery (diameter: 5.7 mm) was found to be wider and shorter than that on the left side (diameter: 3.2 mm). There was a straight left paravertebral venous channel, connected above with the left brachiocephalic vein and later on received left superior intercostal vein and 5th–9th posterior intercostal veins. This was connected below with the hemiazygos vein and a vein from that channel drained into azygos vein at the level of 10th thoracic vertebra (Figure 3). The portion of the artery having constriction was subjected to histopathological examination. It revealed that the tunica media proximal to the constriction was very thick, but at the narrowing site was very thinned out with fluid exudation in between the layers (Figure 4).

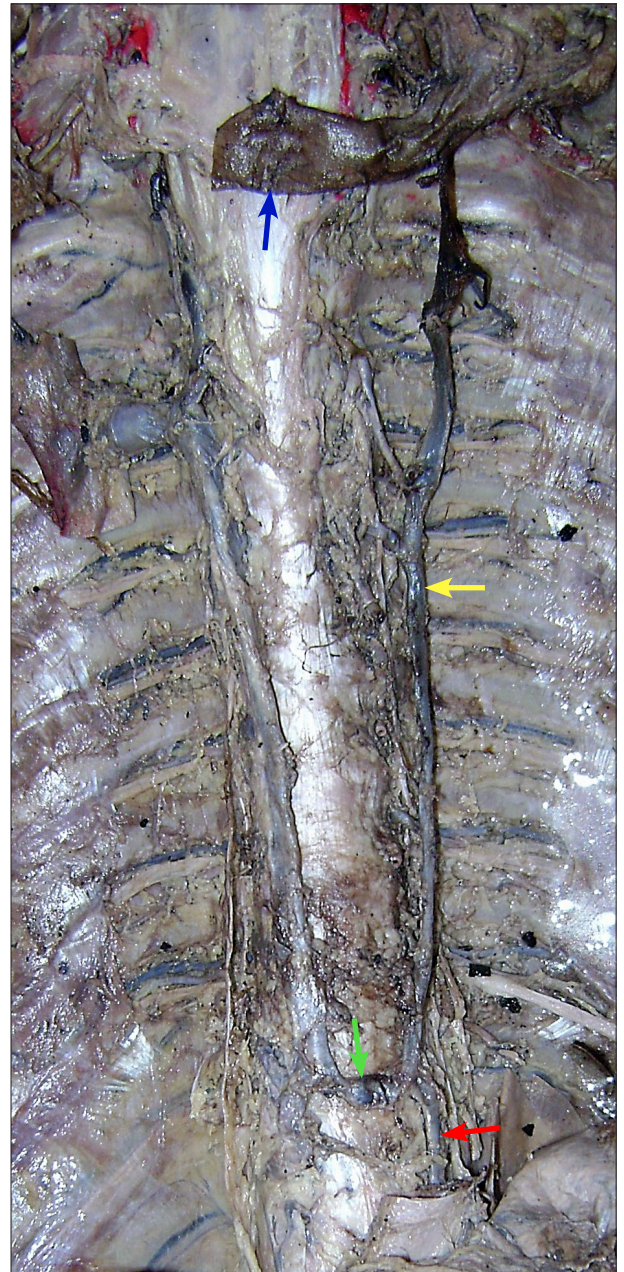### Discussion

Detailed knowledge of mediastinum is absolutely essential for proper radiological interpretation and cardiothoracic surgeries. Left vertebral artery arising from the arch of the aorta, as in our case, is believed to be the most common type of variation in the branching pattern of arch of the aorta. Quain found 5 such amongst 210 cases he studied [2]. Bergman reported this incidence as 5% [3]. In our case the left vertebral artery entered foramen transversarium of the sixth cervical vertebra, though Yamaki et al., had found that in the majority of

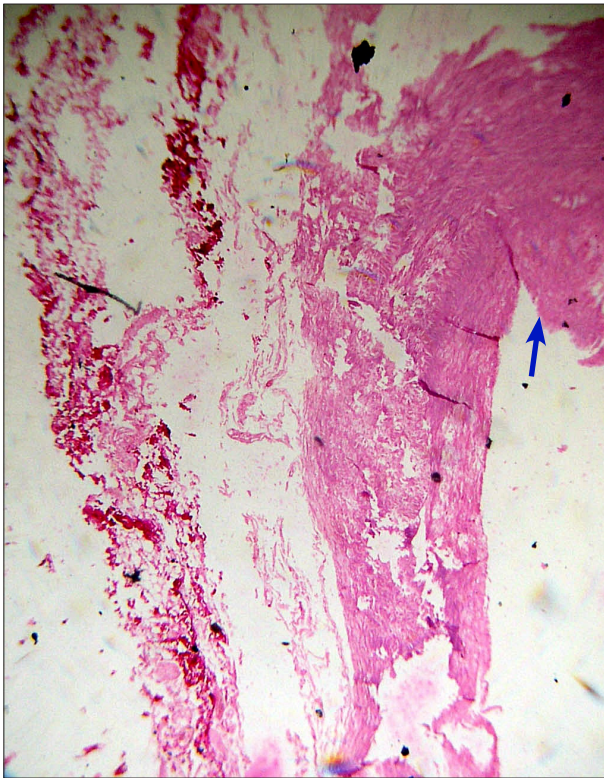
cases (66.7%) left vertebral artery of aortic origin entered foramen transversarium above sixth cervical vertebra in a study of 514 Japanese cadavers [4]. Clinical importance of the left vertebral artery of aortic origin had been emphasised by various researchers, like Bernadi et al., and Poynter. Both opined that vertebral artery of aortic arch origin may precipitate many neurovascular disorders due to change in the cerebral hemodynamic [5,6]. Komiyana et al., while studying 860 left vertebral arteries by angiography had found a higher incidence of



**Figure 2.** The constriction in the left subclavian artery. (Red arrow: the constriction; black arrow: left vertebral artery)



**Figure 3.** Longitudinal venous channel on the left side formed by left brachiocephalic vein, accessory azygos, hemiazygos and transverse communication with azygos vein. (Blue arrow: left brachiocephalic vein; yellow arrow: accessory azygos vein; red arrow: hemiazygos vein; green arrow: transverse communication with azygos vein)



**Figure 4.** Histology of the constricted portion of the artery showing thick tunica media gradually becoming thinner. (Blue arrow: tunica media)

vertebral artery dissection in cases of arch of aorta origin than that of subclavian artery origin [7].

Variations of the azygos venous system are quite common. In a series of 200 cases, Bergman et al. have reported the incidence of this variation as 26%. They had found that the hemiazygos continuous above with the accessory hemiazygos vein (as in our case) in 40% of cases [3]. Accessory hemiazygos vein draining into the left brachiocephalic vein is rare. In our case, accessory azygos vein had communicated below with the hemiazygos vein and above with the left brachiocephalic vein. Definitely it

will act as an important collateral channel when there will be any form of venous obstruction. But more importantly, this communicating vein while going towards the brachiocephalic vein had crossed left subclavian artery and arched along the medial surface of the left lung. This case is against the observation of Quain as he found no hemiazygos vein coming in relation with the subclavian and vertebral arteries [2]. Knowledge of variations of the azygos venous system is necessary since this might be confused with aneurysm, lymphadenopathy and other anomalies like tumor, during radiological investigations [8].

Narrowing of the left subclavian artery was quite significant producing deficiency in the formation of the muscle coat of the artery. Thinness of the muscle coat allowed exudation of fluid within it. Since there was no other space-occupying lesion at that site, most likely cause of the compression, may be by the accessory azygos vein that was going towards the left brachiocephalic vein leading to deficiency in the muscle coat. Thickness of the muscle coat just proximal to the narrowing indicates the excessive workload it undertook to overcome the venous compression and was able to send sufficient blood to ipsilateral upper limb.

#### *Embryological explanation*

The cardiovascular system is the first organ system to reach a functional state. The blood vessels formed first are the simple endothelial tubes, the primitive arteries and veins can't be distinguished structurally. Hemodynamic factors then influence the growth of the endothelium and mesenchymal cells leading to formation of different coats of the vessels. External compression by the accessory azygos vein in our case might have affected mesenchymal cells proliferation leading to almost absent tunica media at that site [9]. Left subclavian artery entirely develops from left 7th inter segmental artery. First part of vertebral artery develops from its dorsal ramus. Left vertebral artery originating from the arch of the aorta is possible if left sixth dorsal intersegmental artery persists or part of the wall of the 7th intersegmental artery is taken up by the arch during its development [10].

#### **References**

- [1] Standring S. Gray's Anatomy. 39th Ed., London, Elsevier Churchill Livingstone. 2005; 1021–1027.
- [2] Quain R. Anatomy of the Arteries of the Human Body. London, Taylor & Walton. 1844; 32, 51.
- [3] Bergman RA, Afifi AK, Miyauchi R. Illustrated Encyclopedia of Human Anatomic Variation: Opus II: Cardiovascular System: Veins: Head, Neck, and Thorax. <http://www.anatomyatlases.org/AnatomicVariants/Cardiovascular/Text/Veins/AzygosAccessory.shtml> (accessed December 2008).
- [4] Yamaki K, Saga T, Hirata T, Sakaino M, Nohno M, Kobayashi S, Hirao T. Anatomical study of the vertebral artery in Japanese adults. *Anat Sci Int.* 2006; 81: 100–106.
- [5] Bernardi L, Dettori P. Angiographic study of a rare anomalous origin of the vertebral artery. *Neuroradiology.* 1975; 9: 43–47.
- [6] Poynter CWM. Arterial anomalies pertaining to the aortic arches and the branches arising from them. *Nebr Univ Stud.* 1918; 18: 229–345.
- [7] Komiya M, Morikawa T, Nakajima H, Nishikawa M, Yasui T. High incidence of arterial dissection associated with left vertebral artery of aortic origin. *Neurol Med Chir (Tokyo).* 2001; 41: 8–12.
- [8] Kocabiyik N, Kutoglu T, Albay S, Yalcin B, Ozan H. Azygos vein system abnormality: case report. *Gulhane Tip Dergisi.* 2006; 48: 180–182.
- [9] Hamilton WJ, Mossman HW. Hamilton, Boyd and Mossman's Human embryology. 4th Ed., London & Basingstoke, The MacMillan Press Ltd. 1972; 228–229, 261.
- [10] Panicker HK, Tarnekar A, Dhawane V, Ghosh SK. Anomalous origin of left vertebral artery – embryological basis and applied aspects – a case report. *J Anat Soc India.* 2002; 51: 234–235.