



Case Report

A rare case of bilateral high division of sciatic nerve (of different types) with unilateral divided piriformis and unusual high origin of genicular branch of common fibular nerve

Published online March 31st, 2011 © <http://www.ijav.org>

Yusuf Saleem KHAN K^[1] ✦
Tasneem Kareem KHAN^[2]

Department of Anatomy & Histology, College of Medicine [1] and College of Humanities [2], Al-Jouf University, Sakaka, KINGDOM OF SAUDI ARABIA.



✦ Dr. Yusuf Saleem Khan K
Assistant Professor of Anatomy & Histology
College of Medicine
Al-Jouf University
P.O. Box No. 2014
Sakaka 75471, Al-Jouf Region
KINGDOM OF SAUDI ARABIA.
☎ +988 55 1021509
✉ doc.anatomy@gmail.com

Received December 6th, 2010; accepted March 6th, 2011

ABSTRACT

We report a very rare case of two different types of high divisions of sciatic nerve (SN) on either side of a 33-year-old female cadaver with unilateral divided piriformis muscle. Here SN of either side divided into tibial and common fibular nerves within pelvis and entered into gluteal region. On the right side both divisions passed below piriformis, but on the left side the common fibular nerve passed between two divisions of divided piriformis, while tibial nerve passed below the inferior piriformis. What is rare is not high division of SN, but to find two different types of high divisions of SN on either side of same cadaver with unilateral bifid piriformis as found here. To our knowledge, there is no literature describing this kind of variation. Also seen was an unusual finding of unilateral high origin of genicular branch of left common fibular nerve. This combination of variations makes this case the most interesting and unique of its kind. © IJAV. 2011; 4: 63–66.

Key words [sciatic nerve] [piriformis muscle] [common fibular nerve] [genicular branch] [variations]

Introduction

Sciatic nerve (SN) is the thickest nerve of body, arising from sacral plexus. Normally it emerges through the greater sciatic foramen, leaves pelvis and enters into gluteal region by passing below piriformis as a single nerve encompassed by a single epineurial sheath. It divides subsequently into two terminal nerves i.e., tibial nerve (TN) and common fibular nerve (common peroneal nerve, CFN), usually at superior angle of popliteal fossa. But sometimes it divides high, while still in pelvis into its terminal branches that leave pelvis in a number of ways. Accordingly they are classified into different types in relations to piriformis muscle (PM). High division of SN is usually unilateral or bilateral mostly leading to compression of nerve resulting in piriformis syndrome, incomplete block of SN during popliteal block anesthesia, etc.

In this case, a very unusual and unique variation in high division of SN was observed.

Case Report

During routine dissection of cadavers for teaching purpose in our institute, it was found that a 33-year-old female Filipino cadaver had bilateral high division of SN. But it was unusual as it showed different types of variation in divisions of SN on two sides in same cadaver. Division of SN into TN and

CFN was within the pelvis bilaterally. However on the right side both divisions of SN entered gluteal region by passing below undivided piriformis (Figure 1). However, on the left side the piriformis was bifid, referred here as superior (larger) and inferior piriformis. The CFN entered gluteal region by passing between two divisions of this piriformis, while TN emerged below lower border of inferior piriformis (Figure 2).

It was also found that left CFN was giving a branch to knee joint (genicular branch). This is normally near superior angle of popliteal fossa. But here, it was giving genicular branch at a much higher level, just 13.5 cm from lower border of inferior piriformis, which is very unusual. This branch then appeared descending distally, parallel and on lateral side of CFN and terminated in capsule of left knee joint (Figure 3).

Discussion

It has been observed that SN usually shows a lot of variations in its division, especially its high division. Smoll pooled results of 18 previous studies and 6,062 cadavers and found that prevalence of this variant in cadavers was 16.9% and in surgical case series was 16.2% [1]. This high division results in sciatica, nerve injury during deep intramuscular injections in gluteal region [2], piriformis syndrome, failed SN block in anesthesia and injury during posterior hip operations.

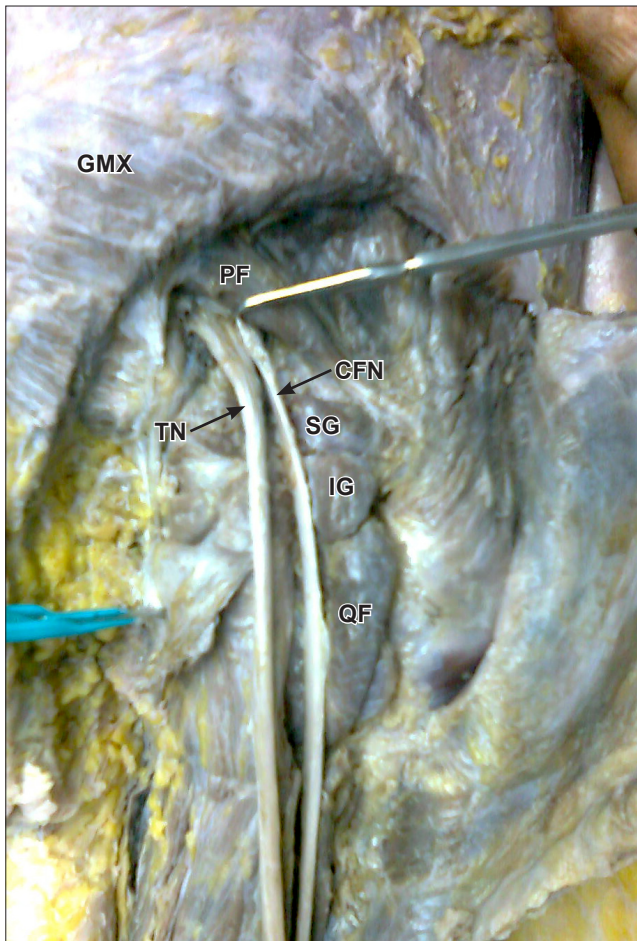


Figure 1. Photograph of the right gluteal region showing high division of sciatic nerve. Both the branches – tibial and common fibular nerve are entering the gluteal region below the piriformis muscle. (*TN: tibial nerve; CFN: common fibular nerve; GMX: gluteus maximus muscle; PF: piriformis muscle; SG: gemellus superior muscle; IG: gemellus inferior muscle; QF: quadratus femoris muscle*)

There are different types of high divisions of SN within pelvis, usually bilateral and if it is unilateral then other side will always remain normal. What is rare is not high division of SN, but rare is it to find two different types of high divisions of SN on two sides in same cadaver as found here. To our knowledge, there is no literature reporting variation of this nature.

Many authors have attempted classification of high divisions of SN. But note that these classifications usually hold good for unilateral or bilateral divisions and can never be properly assigned to our type as it shows two different types of variations on two sides. Hence our attempt to apply these classifications on two sides separately is artificial and it needs a new type of classification in itself. The best known classification is by Beaton and Anson's classification (as cited by Guvencer et al. [3]), which divides all variations under 6 Types. Accordingly our case could be classified

as Type 2 for the right side, whereas we couldn't apply on left side as Beaton mentions only of CFN piercing through piriformis, but doesn't mention of CFN passing between two parts of 'divided piriformis'. Hence this classification should be modified with a new additional classification of Type 7 – divisions of nerve passing between and below divided piriformis muscle. Classification coined by Okraszewska et al., [4] was more suitable and we could assign Type IC to right side and Type IIB for left side (as it doesn't mention divided or undivided PM). These classifications are especially necessary as they help surgeons in assessing cause and site of

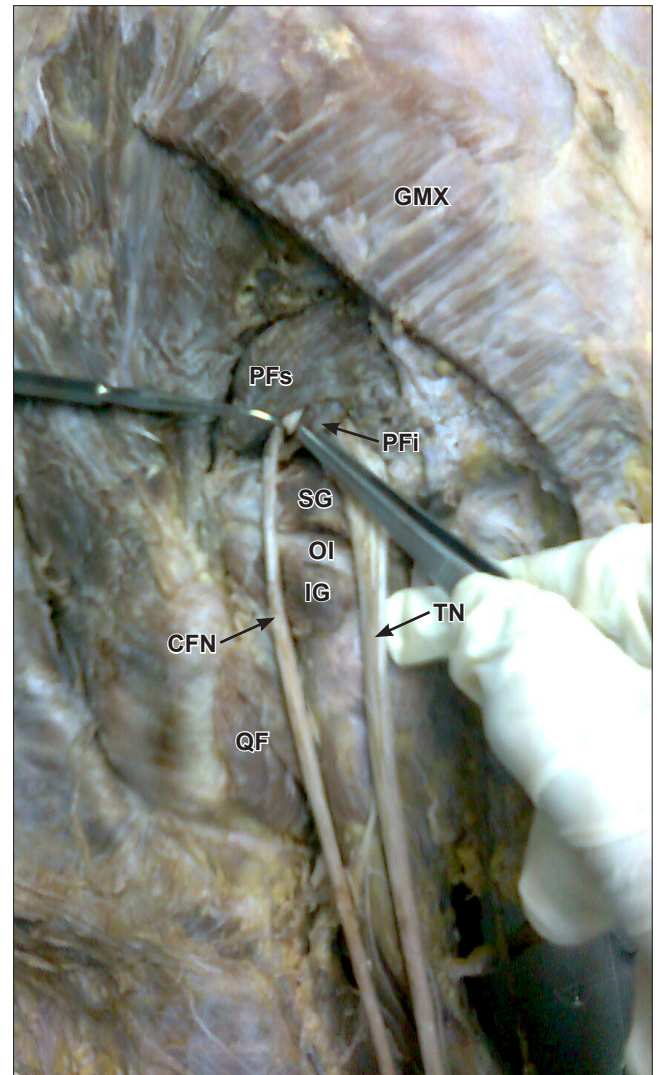


Figure 2. Photograph of the left gluteal region showing high division of sciatic nerve. The tibial nerve passes under the lower border of inferior piriformis but the common fibular nerve passes between the two divisions of piriformis muscle. (*GMX: gluteus maximus muscle; PFs: superior piriformis muscle; PFI: inferior piriformis muscle; SG: gemellus superior muscle; IG: gemellus inferior muscle; OI: obturator internus muscle; QF: quadratus femoris muscle; TN: tibial nerve; CFN: common fibular nerve*)

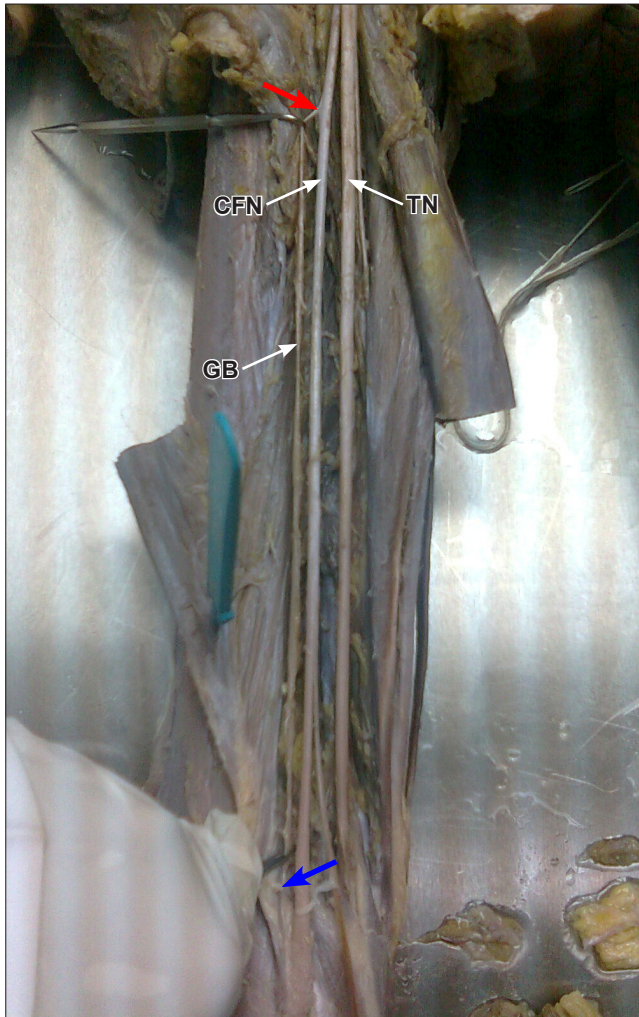


Figure 3. Photograph of the back of left thigh showing the unusual high origin of genicular branch of the common fibular nerve, running on its lateral side and piercing into the capsule of the knee joint. (TN: tibial nerve; CFN: common fibular nerve; GB: genicular branch from common fibular nerve; red arrow: origin of GB; blue arrow: GB piercing the capsule of knee joint)

compression of SN and accordingly treatment differs. This will also alerts them to be more careful during surgeries because of differences on two sides even in same person.

It is usually seen that when SN shows high branching pattern, that one of the branch pierces piriformis. But divided piriformis is not usually seen. Divided piriformis is said to be a very important cause of piriformis syndrome (when present), as CFN passing between two divisions is usually compressed and irritated resulting in the symptoms [5]. Papadopoulos et al. mention that incidence of piriformis syndrome is six times more frequent in females (as our case) [6]. Machado et al. studied 100 gluteal regions [7] and Ugrenovic et al. studied 200 gluteal regions [8], but didn't find even a single divided piriformis. Jawish et al. found

only one case of divided piriformis among 26 cases selected from 3550 cases complaining of sciatica [9]. Demiryurek et al., also mentioned a case of bilaterally divided piriformis [5]. Being it unilateral is still rare [10] as seen in our case, on only left side. Diagnosis of unilateral division of piriformis is very important as this will solve dilemma of surgeons as to why symptoms and signs of piriformis syndrome leading to sciatica differ on two sides in same person and effects of treatment differs and even outcome. Mas et al. [11] have also reported a case of bilateral high division of SN but with tibial nerve passing under gemelleus superior, unlike our case where CFN is passing between two heads of piriformis.

It was also observed that our case had a very unusual unilateral high branching of genicular branch of CFN on left side. It branched just 13.5 cm from lower border of piriformis and descended lateral to CFN and pierced the capsule of knee joint. A similar finding has also been reported by Ali and Eweidah [12], but genicular branching in their case was much below being almost 20 cm from division of SN and running medial to CFN. (Other differences in their case were SN was divided outside pelvis and showed no divided piriformis.) Knowledge of unilateral high branching of genicular branch of CFN is important for surgeons as this nerve can be easily damaged during varicose veins stripping [12].

Combinations of all these variations – two different types of high divisions of SN on two sides, unilateral divided piriformis and unusual unilateral high origin of genicular branch from CFN – makes this as most unique, as well as most interesting among its types.

Anatomical variations in gluteal region such as above are very important for surgeons, as this is the area of frequent surgical manipulation. A thorough knowledge of different variations will not only help surgeon to be careful, but plan accordingly during various surgical interventions and management of this region [13]. This also motivates radiologist to repeat MRI on other side, as there can be differences on two sides. This knowledge is also very important for nurses and junior doctor to prevent deep intramuscular injection hazards in gluteal region [2].

Acknowledgements

No thanks are complete unless it is first to Almighty God who has given us the ability to think and do some work which benefits humankind. Then we are indebt especially to our parents, sisters and brother without whose love and affection we wouldn't have been able to do this work effectively and efficiently. We would also like to thank the Honorable President of our University Prof. Mohammed bin Omar bin Rabee' Badair, the Vice-President Dr. Tarish Al Shamiri, Vice-President and Dean of College of Medicine Dr. Maher Al-Enazi, Ex-Dean Dr. Ahmed Al-Hazmi and all our colleagues, whose trust and support has helped us to complete this work.

References

- [1] Smoll NR. Variations of the piriformis and sciatic nerve with clinical consequence: a review. *Clin Anat*. 2010; 23: 8–17.
- [2] Gonzalez P, Pepper M, Sullivan W, Akuthota V. Confirmation of needle placement within the piriformis of a cadaveric specimen using anatomic landmarks and fluoroscopic guidance. *Pain Physician*. 2008; 11: 327–331.
- [3] Cuvencer M, Iyem C, Akyer P, Tetik S, Naderi S. Variations in the high division of the sciatic nerve and relationship between the sciatic nerve and the piriformis. *Turk Neurosurg*. 2008; 19: 139–144.
- [4] Okraszewska E, Migdalski L, Jedrzejewski KS, Bolanowski W. Sciatic nerve variations in some studies on the Polish population and its statistical significance. *Folia Morphol (Warsz)*. 2002; 61: 277–282.
- [5] Demiryurek D, Bayramoglu A, Erbil M, Aldur MM, Sargon MF. Bilateral divided piriformis muscle together with the high division of the sciatic nerve. *Cazi Med J*. 2002; 13: 41–44.
- [6] Papadopoulos SM, McGillicuddy JE, Albers JW. Unusual cause of 'piriformis muscle syndrome'. *Arch Neurol*. 1990; 47: 1144–1146.
- [7] Machado FA, Bahinski MA, Brasil FB, Favorito LA, Abide-Figueiredo M, Costa MG. Anatomical variations between sciatic nerve and piriform muscle during fetal period in human. *Int J Morphol*. 2003; 21: 29–35.
- [8] Ugrenovic S, Jovanovic I, Krstic V, Stojanovic V, Vasovic L, Antic S, Pavlovic S. The level of the sciatic nerve division and its relations to the piriform muscle. *Vojnosanit Pregl*. 2005; 62: 45–49. (Serbian)
- [9] Jawish RM, Assoum HA, Khamis CF. Anatomical, clinical and electrical observations in piriformis syndrome. *J Orthop Surg Res*. 2010; 5: 3.
- [10] Arifoglu Y, Surucu HS, Sargon MF, Tanyeli E, Yazar F. Double superior gemellus together with double piriformis and high division of sciatic nerve. *Surg Radiol Anat*. 1997; 19: 407–408.
- [11] Mas N, Ozeksi P, Ozdemir B, Kapakin S, Sargon MF, Celik HH, Yener N. A case of bilateral high division of the sciatic nerves, together with a unilateral unusual course of the tibial nerve. *Neuroanatomy*. 2003; 2: 13–15.
- [12] Ali MH, Eweidah MH. A case of a unilateral unusual genicular branch of the common peroneal nerve with bilateral high division of sciatic nerves and unusual bilateral thickness of peroneal communicating nerve. *International Journal of Anatomical Variations (IJAV)*. 2010; 3: 33–35.
- [13] Lal K, Dhar P. A case of unilateral high division of sciatic nerve and bipartite piriformis muscle. *Int Med J*. 2007; 14: 55–58.