

A Rare Anomaly Associated with Nasolacrimal Canalicular System

Sharanbasappa R Japatti, Hamza Mohammed Aarif, Shahbaaz ANaikwade

Japatti RS, Aarif HM, Naikwade SA. A rare anomaly associated with nasolacrimal canalicular system. *Int J Anat Var.* 2020;13(5):29-30.

ABSTRACT

Congenital anomalies associated with Lacrimal apparatus or Nasolacrimal

duct are very rarely recorded with already recorded cases being obstructive in nature and associated with oblique facial clefts. Here we present a case with aberrant opening over infraorbital margin bilaterally mimicing accessory nasolacrimal foramina in a 32-year-old male.

Key Words: Ectopic opening; Lacrimal canaliculi

INTRODUCTION

Ectopic openings or aberrations in the opening of nasolacrimal duct large every rare, so rare that only one or two cases have been recorded [1]. Congenital disruptions and anomalies of this duct system are commonly associated with oblique facial clefts as a result of clefting in this zone [2]. Other congenital anomalies are mostly obstructive in nature and may vary from partial absence of the canalicular system to alacrima. However, such anomalies have never been recorded with the proximal end of the nasolacrimal duct or lacrimal canaliculi that drain into the lateral part of lacrimal sac situated in the lacrimal groove. Here, we present a case of an aberrant opening over the infraorbital margin suspected to be either an extension of lacrimal canalicular system or incomplete formation of the bone surrounding the canal system that mimics accessory nasolacrimal foramen like structure over infraorbital margin medially.

CASE REPORT

A 32 year old male presented with left Para symphysis and right condylar fracture of mandible following a Road Traffic Accident. ORIF under G.A was planned for the same. However, an accidental finding that struck was cleft of soft palate and 3D CT-Face revealing an aberrant opening over infraorbital margin bilaterally supero-medial to infra-orbital foramen. There were no external manifestations of the aberrant opening over the overlying skin. There was no history of pain or excessive lacrimation from either eye the patient otherwise had a normally developed face with no evidence of any cleft (Figure 1).

DISCUSSION

Lacrimal apparatus is a complex structure comprising of lacrimal glands situated on the roof of bony orbit antero-laterally in the lacrimal fossa. Lacrimal gland is a serous gland draining its secretion over conjunctival sac which it lubricates. The excess secretion is manifested as tears and the rest is drained through lacrimal canaliculi (8 mm long) into lacrimal sac situated in lacrimal groove formed by frontal process of maxilla and the lacrimal bone. A nasolacrimal duct (18 mm long) then drains the secretion into inferior meatus of nose. In this case though, an aberrant opening was seen bilaterally over infraorbital margin as accessory nasolacrimal foramen if called so, which can be suspected to exist either due to an extension of the lacrimal canalicular system or incomplete formation of the bone covering the lacrimal canaliculi.

Even though there were no external manifestations of the anomaly encountered, such a rare finding should not be missed as it can have its own clinical significance. For example, one can easily conclude that such an opening over infraorbital margin may weaken its strength and it also can cause changes in the direction of fracture lines in mid-facial trauma which otherwise would produce common presentations of fracture lines in normal skulls. Moreover, surgical procedures like DCR (Dacrocystorhinostomy) may demand an alteration from otherwise normally used techniques due to such variations (Figure 2).

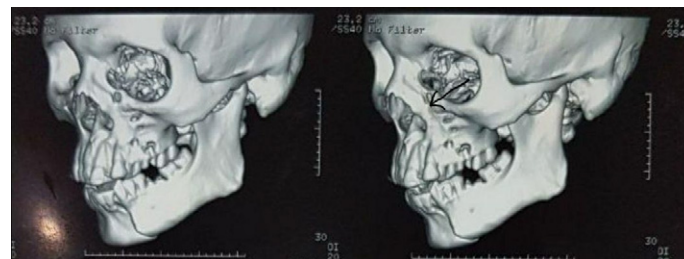


Figure 1) Bilaterally supero-medial to infra-orbital foramen.

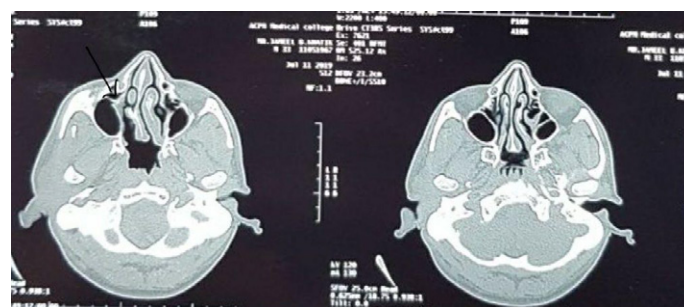


Figure 2) Conjunctival system with nose.

Embryologically there is a zone of mesenchymal condensation in the nasooptic groove, due to the overriding of nasolacrimal process over the medially growing maxillary process, which is the analog of future nasolacrimal duct [3-6]. There are conflicting views as to how this chord of mesenchyme canalizes to connect the conjunctival system with nose. Either the epithelization progresses cranially starting from the caudal end or it occurs craniocaudally or due to coalescences of multiple sacs forming within the rod.

From this case it appears as if the canalization occurs from caudal end to cranial end since the proximal part of canalization was not complete. One more perspective of looking into this case is through the fact that variations in the anatomy of lacrimal bone are commonly recorded. And also, the fact that patient had no external manifestations and involvement of proximal end of the canal may indicate no relation of the cleft of soft palate found in the patient with the aberrancy. So anatomical variations in the lacrimal bone stands as another pillar in the suspected etiology.

CONCLUSION

Craniofacial anomalies bear a great clinical significance in the field of Cranio-maxillofacial surgery and therefore congenital anomalies and anatomic variations should regularly be recorded. This is a very rare case of an aberrant

Department of oral and maxillofacial surgery, Acpm dental college, dhule, India

Correspondence: Dr. Shahbaaz ANaikwade, Department of oral and maxillofacial surgery, Acpm dental college, dhule, India. Telephone +7030784887; E-mail:shahbaaz.naik7@gmail.com

Received: Jul 23, 2020, Accepted: Nov 09, 2020, Published: Nov 16, 2020



This open-access article is distributed under the terms of the Creative Commons Attribution Non-Commercial License (CC BY-NC) (<http://creativecommons.org/licenses/by-nc/4.0/>), which permits reuse, distribution and reproduction of the article, provided that the original work is properly cited and the reuse is restricted to noncommercial purposes. For commercial reuse, contact reprints@pulsus.com

opening over infraorbital margin bilaterally suspected to be associated with the lacrimal canalicular system which needs further research and discussion.

REFERENCES

1. Lowe D, Martin F, Beckenham E, et al. Congenital lower nasolacrimal duct anomaly: A case report. *Aust N Z J Ophthalmol.*1986;14:65-8.
 2. Stretch JR, Poole MD. Nasolacrimal abnormalities in oblique facial clefts. *Br J Plast Surg.*1990;43:463-7.
 3. Datta AK. *Essentials of Human Embryology.* 6th ed., Kolkata, Current Books international. 2010;119-20.
 4. Coats DK, McCreery KM, Plager DA, et al. Nasolacrimal outflow drainage anomalies in Down's syndrome. *Ophthalmology.*2003;110:1437-41.
 5. Breit S, Kunzel W, Opperl M. The course of the nasolacrimal duct in brachycephalic cats. *Anat Histol Embryol.*2003;32:224-7.
 6. Moore BD. Lacrimal system abnormalities. *Optom Vis Sci.*1994;71:182-3.
-