

A Case Report on Advanced Imaging Techniques of Abdominal Protrusion

Michel Karl*

Karl M. A Case Report on Advanced Imaging Techniques of Abdominal Protrusion. *Int J Anat Var.* 2022;15(12):245-245.

ABSTRACT

Retroperitoneal growth is extraordinarily rare, and it happens in only 3%–5% of teratomas. Despite the provision of advanced imaging techniques the medicine doctor need to have in mind the expected anatomy of this type of growth. The aim of our study was to elaborate information concerning

the growth pattern and surgical anatomy of this type of growth. Moreover, anatomical relationship to the secreter was noted. Tumor is Associate in nursing embryonic growth derived from tot potential cells that contain tissue from a minimum of two or a great deal of usually three germ layers in variable proportions. It ought to contain mature and immature tissue components moreover as malignant components.

Key Words: Retroperitoneal; Tumors Expulsion; Unattached retroperitoneal

INTRODUCTION

Despite the provision of advanced imaging techniques the medical science doctor need to have in mind the expected anatomy of this type of neoplasm. In associate degree extremely pioneer study retroperitoneal teratomas beside different types of tumors were described as “unattached retroperitoneal tumors”. Moreover, anatomical relationship to the exocrine gland was noted [1]. Tumour is Associate in nursing embryonic growth derived from tot potential cells that contain tissue from a minimum of two or loads of generally three germ layers in variable proportions. It ought to contain mature and immature tissue components moreover as malignant components.

CASE REPORT

The twelve-month-old woman was brought up our hospital with an outsized abdominal protrusion. There was neither any craving loss nor expulsion. On physical examination a mass of twenty cm in diameter was palpable among the full higher abdomen. Liquid body substance alpha fetoprotein level (22ng/ml) was at the higher border of the age connected confidence interval. Ultrasound confirmed the presence of an outsized heterogeneous abdominal mass. Magnet Resonance Imaging (MRI) unconcealed a fat containing, solid and cystic retroperitoneal tumour with broad contact to the massive vessels (Figure 1) [2]. Right suprarenal region, as a consequence, the exocrine gland was found before of the tumour of each case. Retro pancreatic extension

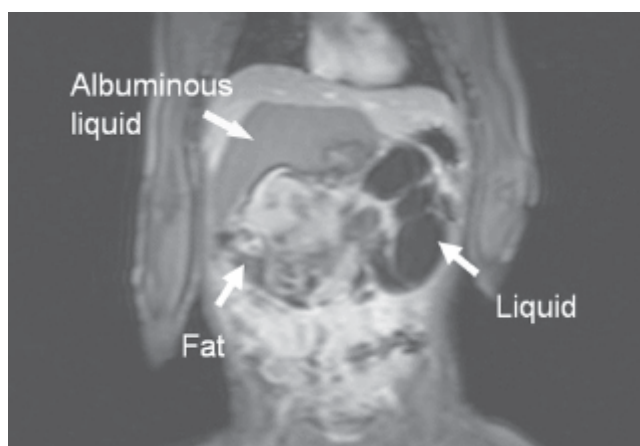


Figure 1) Solid-cystic teratoma containing different types of tissue like fat, albuminous liquid and other solid parts.

could be a well-known feature of adrenal malignant neoplasm and left sided sarcoma. In concern with tumour it's been delineated often in previous papers. For medical diagnosis mature tumour of exocrine gland and also the endocrine gland has been rumored. However, there have been clear surgical plains between the exocrine gland and also the tumour. Moreover, adrenal tissue wasn't found in any of each tumors delineated during this paper [3-4]. The retro pancreatic extension of tumour will be explained by the sex cell theory. Throughout early embryonic development totipotential germ cells migrate from their traditional origin within the nutrient sac on the posterior peritoneum of the viscus to the endocrine gland ridge then to the endocrine gland [5].

CONCLUSION

Incomplete or inaccurate embryonic reproductive cell migration may occur and may be the origin of the neoplasm. The outline of retroperitoneal neoplasm as “unattached retroperitoneal tumor” anatomical relationships of high complexness has got to been taken into consideration if surgery is performed.

ACKNOWLEDGEMENT: None

CONFLICTS OF INTEREST: None.

REFERENCES

1. Hansmann GH, Budd JW. Massive Unattached Retroperitoneal Tumors: An Explanation of Unattached Retroperitoneal Tumors Based on Remnants of the Embryonic Urogenital Apparatus. *Am J Pathol.* 1931; 7(6):631-674.
2. Bruneton JN, Diard F, Drouillard JP. Primary retroperitoneal teratoma in adults: Presentation of two cases and review of literature. *Radiology.* 1980; 134(3):613-616.
3. Gatcombe HG, Assikis V, Kooby D. Primary retroperitoneal teratomas: a review of the literature. *J Surg Oncol.* 2004; 86(2):107-113.
4. Gobel U, Calaminus G, Blohm M. Extracranial non-testicular teratoma in childhood and adolescence: introduction of a risk score for stratification of therapy. *Klin Pädiatr.* 1997; 209(4):228-234
5. Davidson AJ, Hartman DS, Goldman SM. Mature teratoma of the retroperitoneum: radiologic, pathologic, and clinical correlation. *Radiology.* 1989; 172(2):421-425.

Department of Anatomy and Neuroscience, School of Medicine, University College Cork, Cork, Ireland

Correspondence: Michel karl, Department of Anatomy and Neuroscience, School of Medicine, University College Cork, Cork, Ireland. E-mail: michaekarl@ucc.ie

Received: 02-Dec-2022, Manuscript No: *ijav-22-5962*; Editor assigned: 05-Dec-2022, PreQC No. *ijav-22-5962* (PQ); Reviewed: 19-Dec-2022, Qc No: *ijav-22-5962*; Revised: 24-Dec-2022, Manuscript No. *ijav-22-5962*; Published: 31-Dec-2022, DOI:10.37532/1308-4038.15(12).234



This open-access article is distributed under the terms of the Creative Commons Attribution Non-Commercial License (CC BY-NC) (<http://creativecommons.org/licenses/by-nc/4.0/>), which permits reuse, distribution and reproduction of the article, provided that the original work is properly cited and the reuse is restricted to noncommercial purposes. For commercial reuse, contact reprints@pulsus.com